

Research Paper



Role of computed tomography scanner for different phase study of abdomen

Ekta Singh*

*Department of Paramedical Sciences, Radiology, Netherlands.

Article Info

Article History:

Received: 28 August 2024

Revised: 10 November 2024

Accepted: 16 November 2024

Published: 03 January 2025

Keywords:

CT


CT Contrast

Protocols for Abdominal

Scans

TPCT

DSCT



ABSTRACT

This study is aimed to see the different phase of abdomen using computed tomography in various diseases. The study will help the radiographer regarding the patient preparation and protocols are optimized for patient care and well standard. The aim is to see the hemangioma, metastasis, tumor, carcinoma, hepatic vein & portal vein. The research was made on a theoretical examination conducted as a part of daily work. Some facts were taken from many other sources and studies and some were from standard international and national books. The role of computed tomography for different phase of abdominal scan to find out various abnormalities, disease by NCCT OF ABDOMEN, CECT OF ABDOMEN, TPCT, DUAL ENERGY CT. The common cause of different disease observed in my study period includes Metastatic, HCC, Liver abscess, cirrhosis, inflammations, abnormalities, infection in intestines and cortical cyst. This study is to exhibits the common parameter that help to diagnose pathology like metastasis, liver abscess, cirrhosis, inflammations, abnormalities, infection in abdomen, intestinal infection cortical cyst, polyp in large intestine. CT examining is quick, easy, harmless, and exact. Since it can recognize very small nodules in the abdominal scans, Abdomen CT is particularly viable for diagnosing abnormalities of whole abdomen and the organs which comes under in the abdomen, and tumors at most treatable stage. A CT scan creates pictures that can be reformatted in numerous planes. It can even create three layered pictures. Our doctor can audit these pictures on a computer screen, print them on film or through a 3D printer, or move them to a CD or DVD.

Corresponding Author:

Ekta Singh

Department of Paramedical Sciences, Radiology, Netherlands.

Email: ekta75287@gmail.com

Copyright © 2025 The Author(s). This is an open access article distributed under the Creative Commons Attribution License, (<http://creativecommons.org/licenses/by/4.0/>) which permits unrestricted use, distribution, and reproduction in any medium, provided the original work is properly cited.

1. INTRODUCTION

Computed Tomography

CT stands for COMPUTED TOMOGRAPHY it belongs to radiographic technique which uses the x-rays in creating an axial image of the human body. CT scanning also known as computerized axial tomography (CAT). The word tomography is a Greek word in which Tomo means slice, graph means to view. CT scan is a radiographic machine in assessing whole anatomy. CT scan machine use high level x-ray to form image instantly in transverse plane in different flesh with. By using CT scan, abnormalities are detected in sagittal plane or coronal plane with the help of reconstruction in the scan obtain in the monitor [1]. Computed tomography was introduced by SIR GODFREY HOUNSEFIELD at central research laboratories. It gives 3dimensional cross sectional pictures of inward organs and designs. CT filter gives three-layered data on a solitary plane. The CT scanners are utilized to see pictures of inner organs, bones, delicate tissues and veins. It gives data on the size and area of organs. When a restricted light emission beam is directed at a patient, it surrounds the body, which sends signal that are constrained by machine's PC to make cross-sectional images or "cuts" of body. These cuts are alluded to as tomographic pictures, since they consist more data than conventional x-beams. When the machine's PC has gathered various progressive cuts, they can be carefully "stacked" together to produce a three-layered picture of the patient, making it simpler to distinguish and find fundamental designs as well as thought cancers or abnormalities [2].

Basic Principles of Computed Tomography

Multiple projections of an item can be used to rebuild its interior structure. CT records a pattern of densities and creates an image in a "slice" or "cut" of tissue using ionizing radiation (X-rays) and an electronic detector array. Multiple x-ray projections travel through the item while the X-ray beam revolves around it within the scanner [3]. Components of Ct- A Gantry comprising of ring of x-ray tube, detector, collimators, filters. Patient table. Monitor, Pressure injector, Portable electrocardiogram [ECG] machine, and Emergency trolley with drugs. Computed Tomography 128slice Machine Optima Ge Figure 1 shows a modern CT (Computed Tomography) scanner setup in a clinical environment.

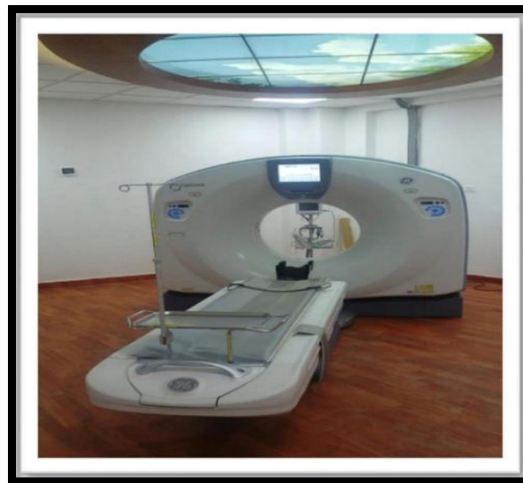

Figure 1. Computed Tomography 128slice Machine Optima GE

CT Scan Working

- a. A CT scanner, not at all like a customary x-beam, utilizes a mechanized x-beam source that pivots around the round entry of a doughnut formed outline known gantry. CT check includes patient lying on a bed that gradually travels through the gantry as an x-beam tube twirls around them, shooting tight light emissions beams through the body. The identifiers get the x-beams as they leave the patient and send them to a PC.

- b. The CT PC utilizes progressed numerical techniques to create a 2D picture cut of the patient each time x-beam finishes one full upheaval. The tissue thickness characterized in each imaging cut fluctuates relying upon the CT gear used, however normally goes from 1 to 10 millimetres.
- c. The picture is saved once an entire cut is finished, and the mechanized bed is gradually positioned into the gantry. Another picture cut is made by rehashing the x-beam examining process. The method has several advantages, which includes the ability to rotate 3D image in space or observe all cuts at once, making it easier to pinpoint the exact location of an issue [4].

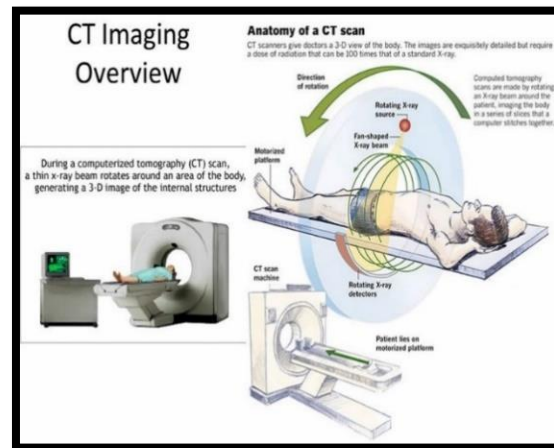


Figure 2. Working of Computed Tomography [1]

Generations of Computed Tomography

First Generation

First Generation Computed Tomography: The original EMI scanner was designed specifically for the evaluation of brain. The X-Ray beam was collimated to get the exact size of the image. In this EMI scanner, the head was enclosed in a water bath, the X-ray tube is above and the detectors below the head. The X-Ray's beam will be ON throughout the linear movement and off during rotatory movement single or double radiation detectors 180° degree translation with one degree radiation translate 5minute image time. It was an oil cooled stationary X-Ray tube with sodium iodide detectors.

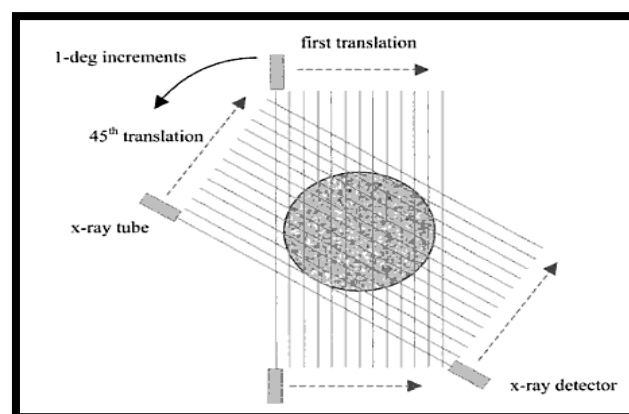


Figure 3. First Generation Computed Tomography

Second Generation

Second Generation Computed Tomography (Rotate Translate System): It has a narrow fan beam (Narrow fan angle of 10 degree). It rotates translate system scan time range from 10s to 90s. It has rotating detectors compared to first generation. It was an oil-cooled stationary X-ray tube with sodium iodide detector. Usually 180° translations with 10° rotation between translations.

1. X-ray beam is picked up by a row of up to 30 detectors.
2. X-ray source and detector then move in synch. (translate)
3. After that, they rotate together to form new image.
4. Continue until only single slice is scanned [5].

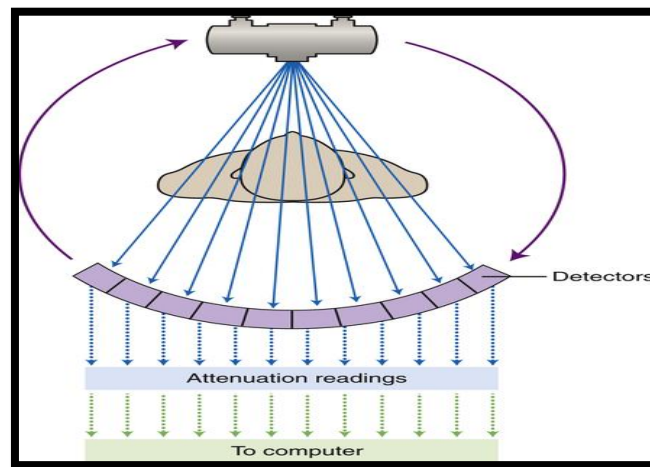


Figure 4. Second Generation of Ct. [6]

Third Generation

Third Generation of Computed Tomography (Wide fan beam) - 360° degree Rotate-Rotate system with wide fan beam multiple detectors rotating with (200 to 700 detectors) no translation required. It moves much faster than second generation (Fast as 0.5s per rotation). Xenon gas detectors are used rather than sodium-iodide detectors used in first two generations. Hundreds of image projections are acquired during each rotation. (Scan time could be 4.9s).

2. RELATED WORK

Rotate-Rotate

X-ray beam collides with a number of detectors that covers the whole slice. They then rotate together to create a new image. The array is switched to different slice once a single slice has been scanned (axial scanning). Alternatively, detector array is continually moved down the patient as it rotates (spiral scanning) [4].

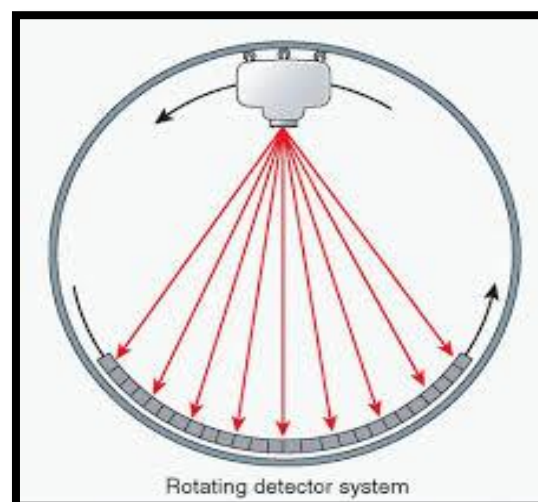


Figure 5. Third Generation of Ct. [2]

Fourth Generation

Fourth Generation Computed Tomography (Rotate stationary system) - Fourth Generation was developed to suppress ring artifacts. Several thousand individual detectors. The tube used in Ct is rotation in motion. As fan beam passes across each detector and images projection is acquired. (Hsieh, 2015)

Rotate-fixed

1. To capture a slice x ray source will rotate around patient body.
 2. Detectors are completely fixed.
 3. Both then move down the patient to begin imaging a different slice
- Not commonly in use.

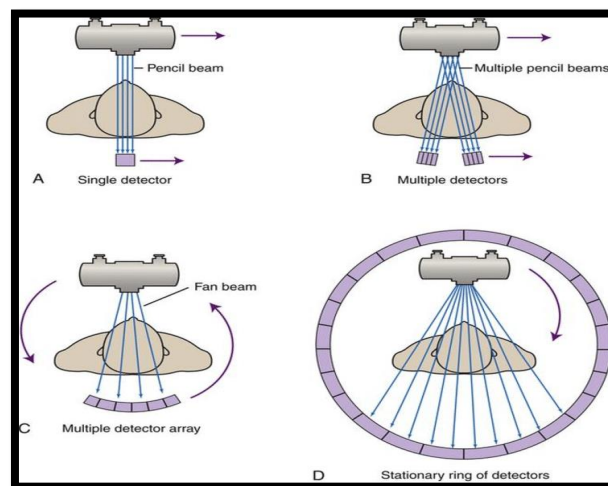


Figure 6. Fourth Generation of Computed Tomography [5]

Fifth Generation

Fifth Generation Computed Tomography 'EBCT' are speed moving CT scan machine, and takes less than 100ms. Stationery-stationary geometry no moving part to this gantry EBCT is principally applied to cardiac imaging.

EBCT consists of wave guide to accelerate an electron beam onto a tungsten target through a bending magnet to that for tissue slices are imaged at the same time. EBCT scan time as short as 50ms. Both x-ray tube and detectors are rotating motion in this generation.

This generation Ct uses cardiac imaging. (Richter, 2022)

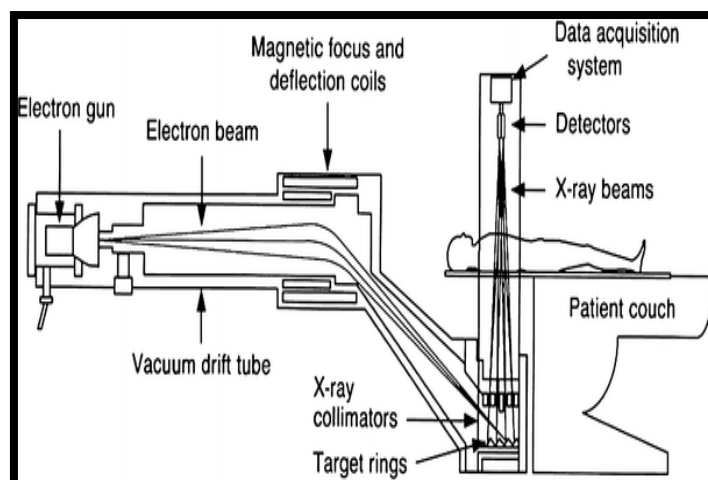


Figure 7. Fifth Generation of Ct [1]

Sixth Generation

Sixth Generation Computed Tomography: 3rd and 4th generations with slip ring technology and helical motion the gantry may revolve constantly since the slip ring is circular in contact with the sliding brushes. The data is received by helical CT scanners while the table is moving. The entire scan time necessary to evaluate the patient, excluding time spent translating the patient table, can be significantly reduced. In rare situations, the full scan can be completed while the patient [5].

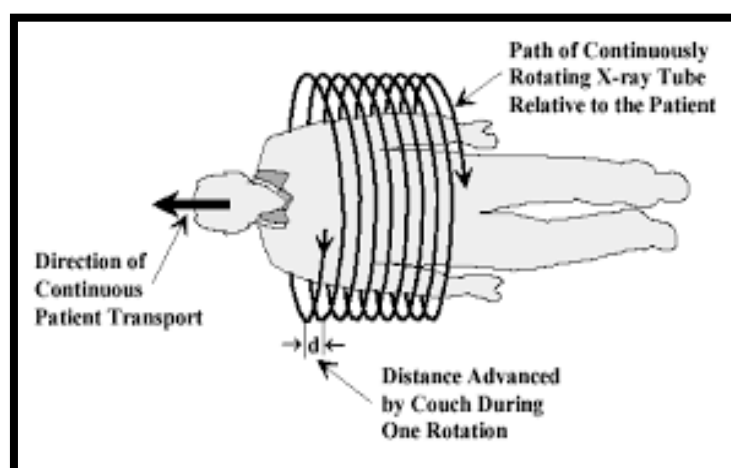


Figure 8. Sixth Generation of Ct. [7]

1. Left iliac region
2. Hypogastric region [7]

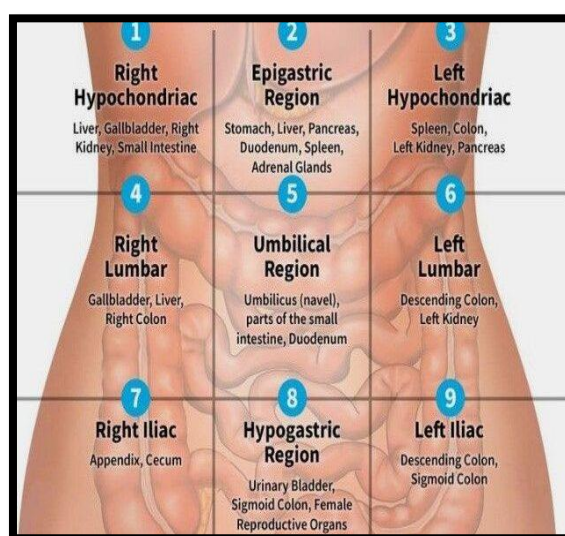


Figure 9. Quadrants of Abdomen [8]

Abdomen Anatomy

The abdomen is consisting primarily of the digestive tract and other accessory organs which assist in digestion, the urinary system, spleen and the abdominal muscles. The majority of these organs are encased in protective membrane termed the peritoneum.

While the digestive organs and assessor organs are located within peritoneum, the kidneys, ureters and urinary bladder are located outsider of the peritoneum, and thus are considered by pelvic organs [8].

Computed Tomography Anatomy of Abdomen

When examining the abdomen through the CT scan it is important to use a systematic approach. This means that the examiner needs to be focused on one organ at the time and that every abdominal organ needs to be evaluated individually and thoroughly. Additionally, when a patient comes with a specific clinical presentation (Bone fracture) the radiologist should not focus only on one structure, but rather on the entire scan. These techniques minimize the possibility of missing out on small structural changes and incidental findings that the patient may have. One of the recommended approaches includes the following steps
Examine anatomical borders of the region. Identify the scan level with anatomical landmarks; diaphragmatic vault:

- (T10-T11), celiac trunk (T12), superior mesenteric artery (L1), renal arteries (L2-L3) and aortic bifurcation (L4).
- Analyse the peritoneal cavity and retroperitoneal space.
- Review the organs by dividing them into hollow and solid.

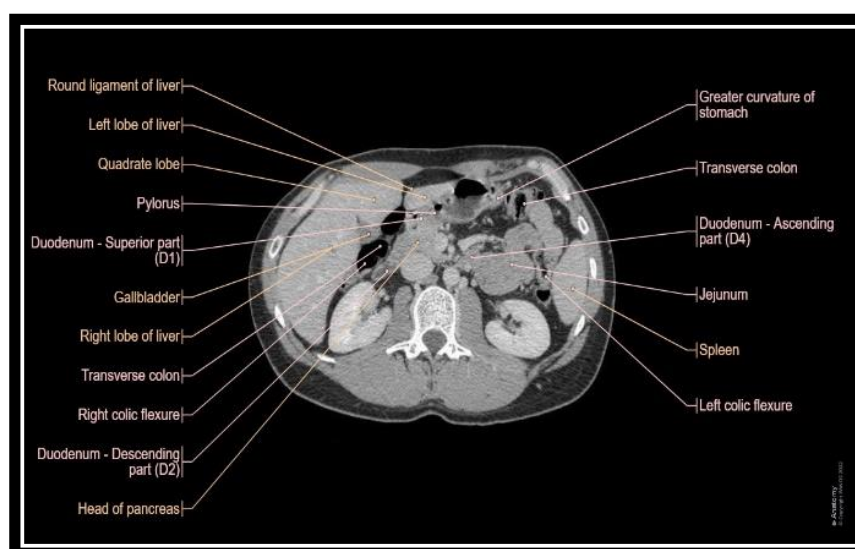


Figure 10. Anatomy of Abdomen [9]

Dr V. K Verma & Dr. Neelam Soni

Comparison of triple segment Ct and USG findings for assessment of hepatic lesions. Dr (Mrs.) Lovely Kaushik, Professor Head of the Department, Dr. V. K Verma, Associate Professor, Dr. Neelam Soni, all authors are affiliated with Department of Radio prognosis and Imaging, Gandhi Medical College, Bhopal, Madhya Pradesh, India. Characterizing a hepatic lesion as benign or malignant is vital for proper healing plan and surgical triage. USG performs important position in screening of a liver lesion. Conventional CT with most effective portal venous segment has sure barriers inclusive of its incapacity to come across lesions which complements in early arterial segment like HCC and people improving in not on time segment like Cholangiocarcinoma. Triphasic CT makes use of 3 stages and gives a complete and correct determination. Design: This potential protected one hundred sufferers with scientific suspicion of hepatic masses [4].

C Marie-Ange Labra

This changed into performed through C Marie-Ange Labra, Computerized Medical Imaging and Graphics 76, 101635, 2019 on the subject of growing techniques to phase the liver in scientific snap shots, look at and examine it stays a sizable challenge. The form of the liver can range significantly from one affected person to another, and adjoining organs are visualized in scientific snap shots with comparable intensities, making the limits of the liver ambiguous. Consequently, automated or semi-automated segmentation of liver is a tough task. Moreover, scanning structures and magnetic resonance imaging have special settings and parameters. the snap shots received fluctuate from one machine [9].

Schaijik, Jennifer de Jongh

202 on the subject infantile hemangioma (IH) influences 4-10% of children. 1-three It is characterised with the aid of use preliminary fast proliferation observed with the aid of using spontaneous gradual involution, frequently leaving a fibrofatty residuum. 4, five Fetoprotein (AFP) is a serum boom component produced with the aid of using the liver at some point of fetal liver development/regeneration and in hepatic cancer [5].

Radiotherapy on Pulmonic Hepatoid Adenocarcinoma along Intrahepatic Hemangioma: report focus and remedy 13, 11947, 2020 'Extrahepatic adenocarcinoma with hepatocyte differentiation is known as hepatoid adenocarcinoma and is characterised by high malignancy and a poor prognosis. Then they file the investigate, remedy and group of affected persons who is suffering from pulmonic hepatoid adenocarcinoma and they have only radiotherapy. Affected person OF 41Y antique guy identified along neighbour who is suffering from lung cancer [2]

Jun Gao, Li Xu, Meng-meng Yang

This examine changed into executed through Jun Gao, Li Xu, Meng-meng Yang, on the subject haemangiomas A extreme worry of myocardial disorder put up radiofrequency ablation remedy of big hepatic hemangioma: In current time, RF surgery are an increasing in number to help in diagnosis hepatic hemangiomas credit for specific benefit, consisting minimum painful procedure, particular efficiency, excessive secure, rapid recuperation, and extensive applicability. they suggested a case of extreme myocardium disorder in conjunction along routine inflammation reaction symptoms taking place right away put RF therapy almost 10.7 cm haemangiomas [10].

3. METHODOLOGY

Patient Prepration

Firstly, patient's previous history is taken. Patient's 4 to 6 hours fasting mandatory if examination is with contrast. Always ask the female patients about their LMP and pregnancy.

Kidney function test report (KFT) must be normal- mandatory for contrast exam. Normal value of Urea-20.00 to 43.00 mg/dl and Creatinine - 0.6 to 1.2mg/dl

Oral Contrast

1 Litter normal water and 10 to 20 ml contrast mix, ask the patient to drink it for 1.5 hours. Ask pt to remove all metallic things and change all clothes and wear hospital gown. Most important thing is to take the patient's consent form, allergy history, patient signature and name before the examination.

The image displays two versions of a 'Consent Form (CT SCAN)'. The left version is a printed form with fields for Patient Name, ID, and Signature, and a table for medical history. The right version is a digital form with a 'MAJOR' section for risks and a 'MINOR' section for side effects, both requiring patient or guardian signature and date.

Figure 11. During Procedure Consent form in CT scan

Procedures for Different Phase of Abdomen

1. Non- contrast computed tomography [NCCT]
2. Contrast enhanced computed tomography [CECT]
3. Triple phase computed tomography [TPCT]
4. Dual phase computed tomography
5. Ct angiography of abdomen
6. Ct colonoscopy
7. Ct urography

Protocols for Noncontrast Computed Tomography for Abdomen

Non-contrast computed tomography [NCCT] scan for the whole abdomen is a diagnostic imaging test used to create detailed images of internal organs, bones and blood vessels.

Indications

Screening, Detection and confirmations of the lesions, Follow up cases.

Contraindications

Pregnancy

Exposure Rate

KvP- 100-120

MAs- 300

Patient Preparations

Explain the procedure to the patient and ensure that patient must be in a stable condition.

Consent form must be taken to the patient.

Remove all the metallic objects from area of examination.

Breath-hold procedure must be explain to pt before the exam.

Patient Position

Patient must be in supine condition, with head first or feet first according to need.

Hand of patient must be extended up to the region of head and legs must be fully extended.

Scout must be taken in Antero-posterior [AP] Position for planning and patient positioning.

Scan Orientation

It can be cranio- caudal or caudo-cranial.

Starting Point: above the diaphragm.

End Point: Below to symphysis pubis.

Slice Thickness: 7-10mm

Pitch: =1

Centering: at the level of diaphragm.

Image Characteristics

Kidneys must be included.

Liver must be included.

Whole abdomen includes liver, kidneys pancreas, small intestine, gall bladder and pelvis also.

3d Reconstruction: MPR, MIP VRT CASE

a. Patient Name: ABC

b. Patient History: pt presented with the complaint of right flank pain.

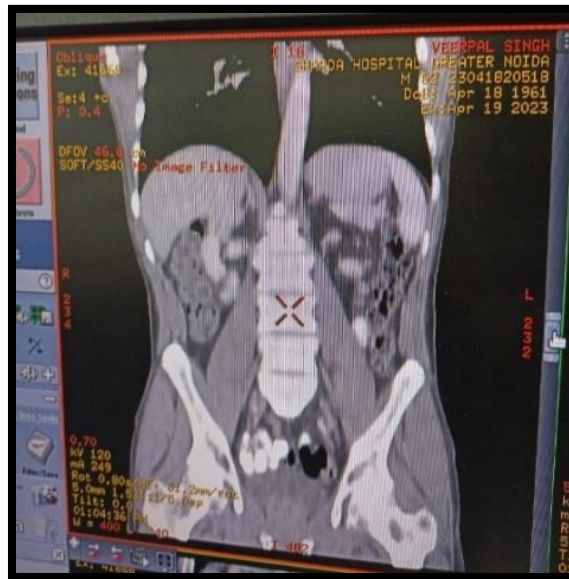

Figure 12. Ncct Abdomen

Contrast Enhanced Computed Tomography for Abdomen

CECT whole abdomen is a diagnostic imaging tool used to create detailed images of internal organs, bones soft tissues.

Indications

Screening
Suspected or known tumor, fluids, cyst, lesions.
Follow up cases.

Contraindications

Pregnancy
Contrast media allergies.

Exposure Rate

Kvp-100-120

MAs-300

Patient Preparations

Explain the procedure to the patient and ensure that patient in a stable condition.

Consent form must be taken from patient.

Kidney function test report (KFT) must be normal- mandatory for contrast exam.

Normal value of Urea-20.00 to 43.00 mg/dl

Creatinine - 0.6 to 1.2mg/dl

Remove all the metallic objects from area of examinations and breath- hold procedure must be explain to patient before exam.

Oral contrast media 10-20ml of contrast is mixed with 1lit of water and given to the patient 1hr prior to exam to drink and left 10ml from that for test dose.

Patient Position

Head first, supine with arms extended above the level of the head.

Scout must be taken in AP for patient positioning and planning of scanning.

Scan Orientation: cranio-caudal

Starting Point: above the diaphragm

End Point: below to symphysis pubis.

Slice Thickness: 7-10mm

Pitch: =1

Mode of Scanning: Helical

Contrast Media: ORALLY-10-20ml mixed with 1lit of water.

Intravenously: 100ML with using PRESSURE INJECTOR.

Rate of Flow: 2-3ml/sec.

Centering: at level of diaphragm.

Image Characteristics

Whole abdomen must be included and all organs like, liver, kidney, small intestine, gall bladder, pelvis etc.

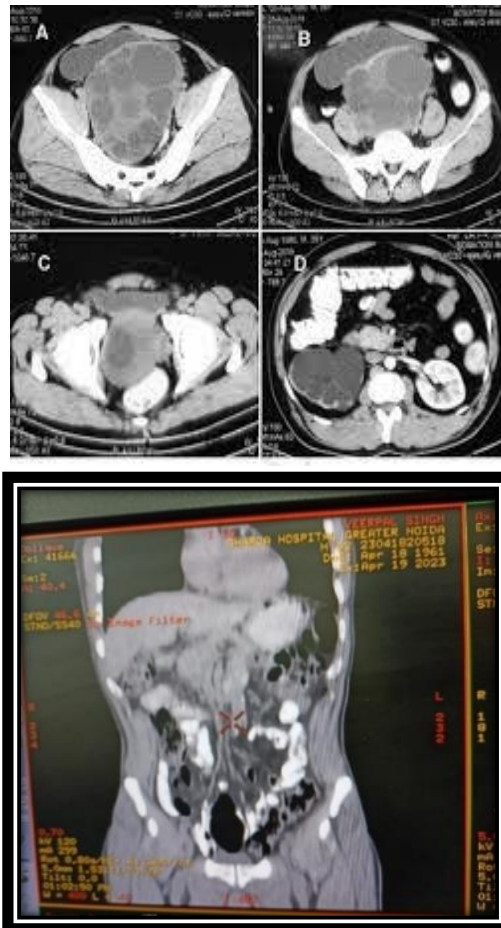


Figure 13. Cect of Abdomen

3d Reconstruction: MIP, VRT, MPR

Triple Phase Computed Tomography

TPCT: liver is a useful exam in the assessment of focal liver lesion, hyper vascular lesion metastasis and endocrine tumors. It includes arterial, venous and portal phase.

Indications

Suspected cirrhosis or hepatocellular carcinoma as well as benign primary liver neoplasm like focal nodular hyperplasia or adenoma.

Contraindication

Pregnancy
Contrast media allergies

Exposure Rate**kVp-** 120-150**mAs-** 300**Patient Preparations**

Explain the procedure to the patient and ensure that patient in a stable condition.

Consent form must be taken from patient.

Kidney function test report (KFT) must be normal- mandatory for contrast exam.

Normal value of Urea-20.00 to 43.00 mg/dl

Creatinine - 0.6 to 1.2mg/dl.

Remove all the metallic objects from area of examinations and breath- hold procedure must be explain to patient before exam.

Oral contrast media 10-20ml of contrast is mixed with 1lit of water and given to the patient 1hr prior to exam to drink and left 10ml from that for test dose.

Patient Position

Head first, supine with arms extended above the level of head.

Scout must be taken in AP for planning and patient positioning.

Scan Orientation: Craniocaudal for arterial and caudocranial for portal to venous phase.

Starting Point: 1cm above the dome of diaphragm for arterial.

Ending Point: lower poles of kidneys for arterial, in venous start and end points are reversed.

Contrast Administration: ORALLY-10-20ml mixed with 1lit of water.

INTRAVENOUSLY- 100ML with using PRESSURE INJECTOR.

Rate of Flow: 5ml/sec

Arterial phase is acquired at a scan delay of approximately 10sec after initiation of contrast injection by arterial bolus tracking.

Portal venous phase is acquired at scan delay of 30sec.

Slice Thickness: 3mm

Pitch: =1

3d Reconstruction: MIP, VRT, MPR

NOTE: In suspected cases of cholangiocarcinoma, a delayed phase is acquired at 15min after initiation of contrast.

Case

Patient Name: XYZ

Patient History: liver abscess

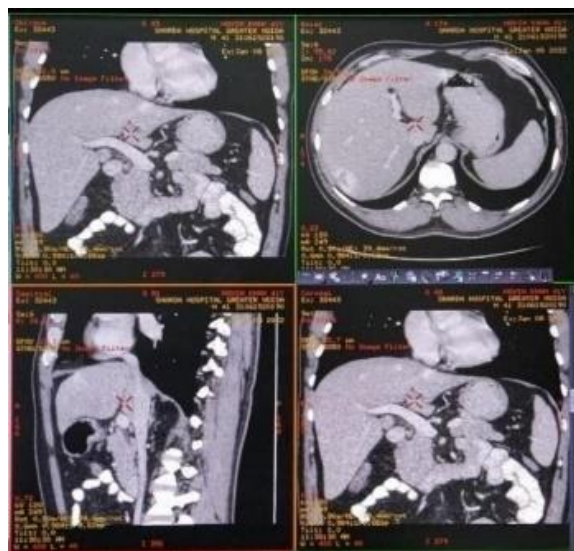

Figure 14. The Fig Show Arterial Phase

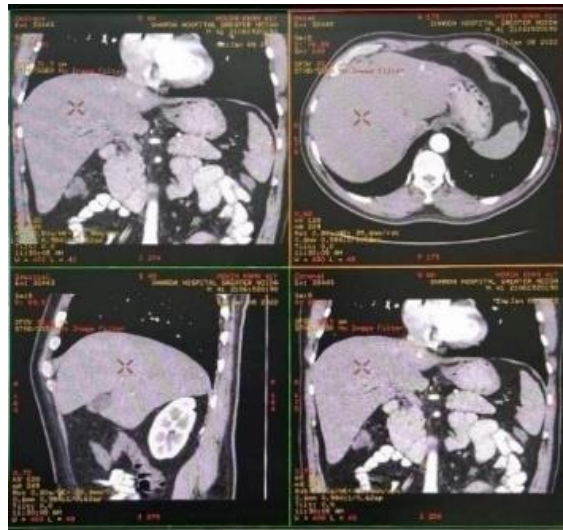

Figure 15. The Fig Show Portal Phase

Patient present with the history of Liver abscess under the TPCT procedure study done shows that the Multiple Liver lesion are described above likely Hemangiomas, Cholelithiasis Dual Source Computed Tomography DSCT is a CT system with two x-ray tubes and two detectors at any angle of approximately 90 degree. Both measurement systems acquired CT scan data simultaneously at same anatomical level of patient.

Indications

Screening

Suspected or known tumor, fluids, cyst, lesions.

Follow up cases.

Contraindications

Pregnancy

Contrast media allergies.

Exposure Rate

Kvp-100-120

MAs-300

Patient Position

Head first, supine with arms extended above the level of the head.

Scout must be taken in AP for patient positioning and planning of scanning.

Both scout and contrast images should take simultaneously.

Scan Orientation: cranio-caudal

Starting Point: above the diaphragm

End Point: below to symphysis pubis.

Slice Thickness: 7-10mm

Pitch: =1

Mode of Scanning: Helical

Contrast Media: ORALLY-10-20ml mixed with 1lit of water.

INTRAVENOUSLY- 100ML with using PRESSURE INJECTOR.

Rate of Flow: 2-3ml/sec.

Centering: at level of diaphragm.

Image Characteristics

Whole abdomen must be included and all organs like, liver, kidney, small intestine, gall bladder, pelvis etc. Fast imaging than normal CT as use two detectors.

4. RESULTS AND DISCURSION

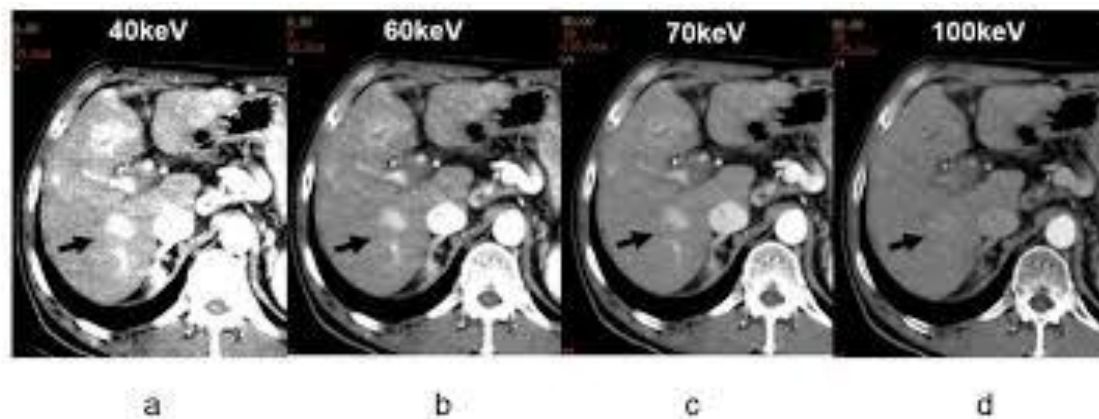


Figure 16. Dual Source Computed Tomography

3d Reconstruction: MIP, VRT, MPR.

Protocol for Computed Tomography Angiography for Abdomen Indications

Screening and evaluation of aneurysms of abdomen.

Rupturing and retroperitoneal hemorrhage.

Infection and disease.

Follow up cases.

Contraindications

Pregnancy and contrast allergies.

Patient Position

Head first, supine with arms extended above the level of head.

Scout must be taken in AP for planning and positioning of patient.

Kidney function test report (KFT) must be normal- mandatory for contrast exam.

Normal value of Urea-20.00 to 43.00 mg/dl

Creatinine - 0.6 to 1.2mg/dl

Mode of Scanning

Helical with single breath-hold.

Scan Orientation

Craniocaudal-[towards the head]

Starting Point: 1cm above the highest point of dome of diaphragm.

Ending Point: 1cm below the apex of prostate.

Gantry Tilt: Nil

Contrast Medium: ORALLY-10-20ml mixed with 1lit of water.

INTRAVENOUSLY- 100ML with using PRESSURE INJECTOR.

Rate of Injection of Contrast: 3-5 ml/sec.

Slice Thickness: 1-2mm

Scan Delay: 15-20sec.

3d Reconstruction: MPR, MIP, VRT

Case

a. **Patient Name:** ABC

b. **Patient History:** pain and inflammation in abdominal area.

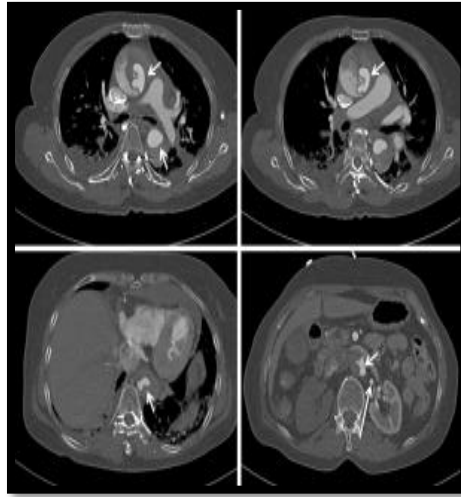


Figure 17. Ct Angiography

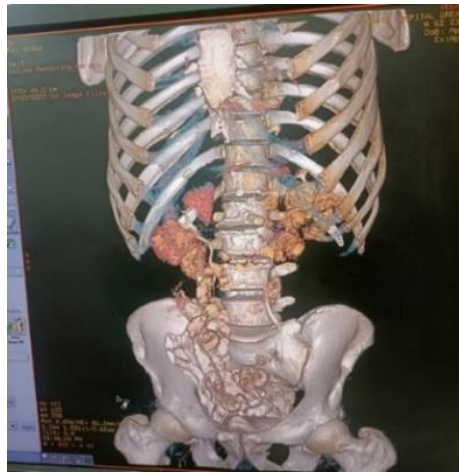


Figure 18. 3d Ct Angiography

Protocol for Computed Tomography Colonoscopy

Indications

Symptoms of colorectal cancer
Carcinoma
Screening for colorectal cancer
Follow up after polypectomy
Incomplete or failed colonoscopy.

Contraindications

Pregnancy and contrast allergies.

Exposure rate:

Kvp- 120-200

mAs – 300

Kidney function test report (KFT) must be normal- mandatory for contrast exam.

Normal value of Urea-20.00 to 43.00 mg/dl

Creatinine - 0.6 to 1.2mg/dl

Patient Position

Head first, supine with arms extended above the level of head.

Scout must be taken in AP for planning and patient positioning.

Mode of Scanning

Helical

Scan Orientation: craniocaudal [towards the head]

Starting Point: 1cm above the diaphragm.

Ending Point: 1cm above below the apex of prostate.

Gantry Tilt: Nil.

Contrast Media: Rectally

Volume of Contrast: carbon dioxide/ air is insufflated rectally.

Slice Thickness: 3-5 mm

3D Reconstruction: MIP, VRT

Comments

The first step in CT COLONOSCOPY is bowel preparation which is done by any method-

First, low residue diet with thorough bowel catharsis.

Second, low residue diet, mild bowel catharsis with fecal tagging.

Fecal tagging done by-

250ml pf 1-3% barium sulfate 3times a day for 48hr before examination.

CASE:

- Patient name: ABC
- Pt history: pain and inflammation in abdomen since 2 months.

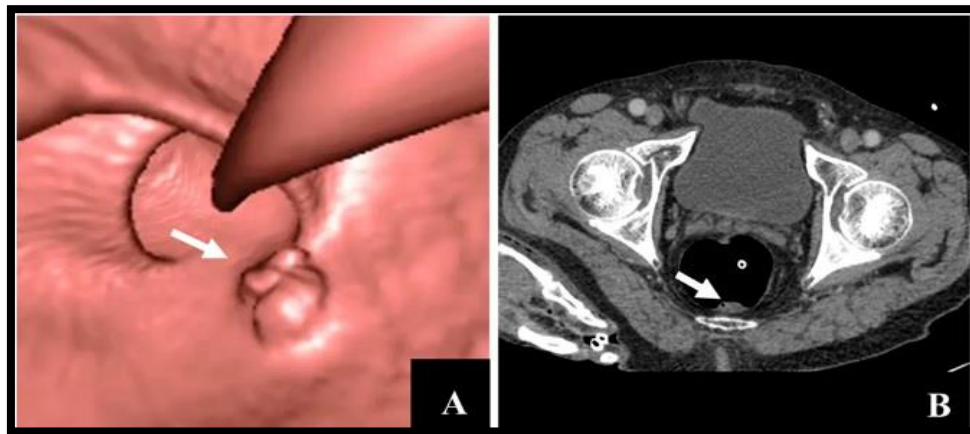


Figure 19. Ct Colonoscopy [A- Showing the Polyp Formation in Large Intestine]

Protocol for Computed Tomography Urography

Indications

Screening and evaluation in renal masses and their differential diagnosis.

Contraindications

Pregnancy

Contrast allergies.

Exposure Rate

Kvp – 120-200

mAs- 300

Kidney function test report (KFT) must be normal- mandatory for contrast exam.

Normal value of Urea-20.00 to 43.00 mg/dl

Creatinine - 0.6 to 1.2mg/dl

Patient Position

Head first, supine with arms extended above the level of head.

Scout must be taken in AP for planning and positioning of patient.

Mode of Scanning

Helical with single breath-hold.

Scan orientations: caudocranial in the nephrographic phase and craniocaudal in the excretory phase.

Starting Point: highest point on the iliac crest.

Ending Point: 1cm above the highest point of dome of the diaphragm.

In excretory phase the starting and end location are reversed in the nephrographic phase.

Gantry Tilt: Nil

Contrast Administration: Orally, Rectally, Intravenous.

Rate of Injection: 2-3ml/sec.

Scan Delay: 35-45 sec for the nephrographic phase and 60-80sec for excretory phase.

Slice Thickness: 3-5mm 3D reconstruction: MIP, MRP, VRT.

Case

Patient Name: XYZ

Patient History: pain and swelling in abdominal area, problem in urination.

Impression: mild ascites is seen in abdominal area.

This study is aimed to see the different phase of abdomen using computed tomography in various diseases. The study will help the radiographer regarding the patient preparation and protocols are optimized for patient care and well standard. The aim is to see the hemangioma, metastasis, tumor, carcinoma, hepatic vein & portal vein.

The role of computed tomography for different phase of abdominal scan to find out various abnormalities, disease by NCCT OF ABDOMEN, CECT OF ABDOMEN, TPCT, DUAL ENERGY CT etc. The common cause of different disease observed in my study period includes Metastatic, HCC, Liver abscess, cirrhosis, inflammations, abnormalities, infection in intestines and cortical cyst. It is particularly viable for diagnosing abnormalities of whole abdomen and the organs which comes under in the abdomen, and tumors at most treatable stage. Computed tomography scan creates pictures that can be reformatted in numerous planes. It can even create three layered pictures. Our doctor can audit these pictures on a computer screen, print them on film or through a 3D printer, or move them to a CD or DVD. This study was to take a look that been to take a look at the function capabilities of numerous hepatic lesions the usage of triple segment Computed tomography for testing modality.

Chandra Prakash Ahirwar, Abhijit Patil

This changed into completed through Chandra Prakash Ahirwar, AbhijitPatil, Neelamsoniat. el., in this subject matter Liver is susceptible to numerous sicknesses along with benign and malignant due to its main characteristic of digestion, cleansing and wealthy blood deliver through the portal veins and the hepatic arteries. Objectives to this study was to take a look that been to take a look at the function capabilities of numerous hepatic lesions the usage of triple segment Computed tomography for testing modality. Over all a hundred sufferers had been enrolled on this cross [7].

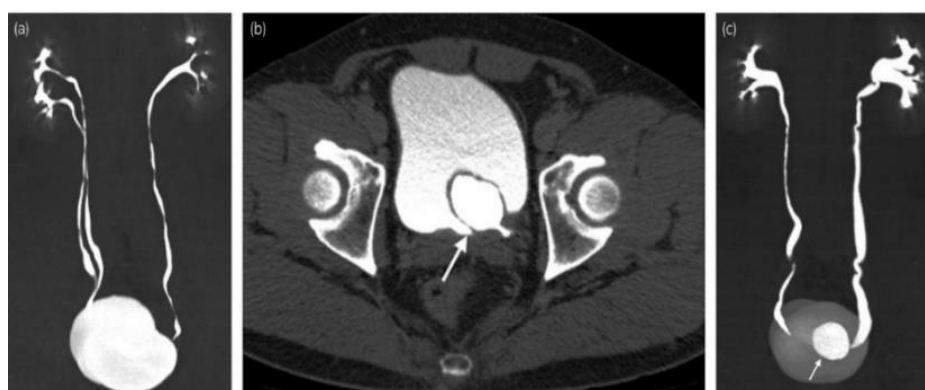

Figure 20. Computed Tomography Urography

The Computed Tomography scan very effective to find out pathologies and abnormalities in abdominal area with different phases. It is a non- invasive treatment that is relatively safe, though it does include increased radiation exposure. This study is to exhibit the common parameter that help to diagnose

pathology like metastasis, liver abscess, cirrhosis, inflammations, abnormalities, infection in abdomen, intestinal infection cortical cyst, polyp in large intestine. It also form 3D images which are more useful to differentiate any pathology with using volume rendering technique [VRT], multiplanar reformation [MPR], Shaded surface display [SSD] etc.

5. CONCLUSION

A CT scan is a radiological diagnostic method that produces an image of a specific organ or structure within the body using a mix of x-Rays and detectors. The CT scan is a diagnostic procedure that uses the principal of reconstruction to create image of the human body. A CT scan of the abdomen provides detailed image of the different phases of abdominal scans including CTA, NCCT OF ABDOMEN, CECT, COLONOSCOPY, UROGRAPHY, to find out pathologies, abnormalities and other problems can all visualized with this technique. The CT scan is a non- invasive treatment that is relatively safe, though it does include increased radiation exposer. This study is to exhibits the common parameter that help to diagnose pathology like metastasis, liver abscess, cirrhosis, inflammations, abnormalities, infection in abdomen, intestinal infection cortical cyst, polyp in large intestine.

Acknowledgments

The author sincerely acknowledges the support and guidance provided by the Department of Paramedical Sciences, Radiology, Netherlands, in carrying out this study. Special thanks are extended to the clinical radiology team for their valuable input on imaging protocols and patient care standards. The author is also grateful to the researchers and professionals whose studies and references have contributed to this work.

Funding Information

No specific grant from any funding agency in the public, commercial, or not-for-profit sectors was received for this research. The study was carried out as part of academic and clinical practice activities.

Author Contributions Statement

Name of Author	C	M	So	Va	Fo	I	R	D	O	E	Vi	Su	P	Fu
Ekta Singh	✓	✓	✓	✓	✓	✓		✓		✓	✓	✓	✓	

C : Conceptualization

M : Methodology

So : Software

Va : Validation

Fo : Formal analysis

I : Investigation

R : Resources

D : Data Curation

O : Writing - Original Draft

E : Writing - Review & Editing

Vi : Visualization

Su : Supervision

P : Project administration

Fu : Funding acquisition

Conflict of Interest Statement

The author declares no conflicts of interest related to the preparation, content, or publication of this manuscript.

Informed Consent

The study did not involve direct experimentation on human subjects or animals. All data and imaging protocols mentioned are based on standard clinical practices and published guidelines. Patient privacy and confidentiality were strictly maintained, with no personal identifiers included in the study.

Data Availability


The data supporting this research are derived from standard imaging protocols and clinical practice references. Any additional details regarding imaging parameters, phases of abdominal CT scans, or study-related materials can be made available by the corresponding author upon reasonable request.

REFERENCES

- [1] A. Bhide, S. Datar, and K. Stebbins, 'Case histories of significant medical advances: Computed tomography', SSRN Electron. J., 2019. doi.org/10.2139/ssrn.3429976
- [2] C. Liguori, 'Emerging clinical applications of computed tomography', Medical Devices: Evidence and Research, vol. 8, pp. 265-278, 2015. doi.org/10.2147/MDER.S70630
- [3] T. Flohr, 'CT systems', Curr. Radiol. Rep., vol. 1, no. 1, pp. 52-63, Mar. 2013. doi.org/10.1007/s40134-012-0005-5
- [4] Edyvean, S. and Gelijns, J. (2013) Chapter 11: Computed Tomography, Journal of Medical Imaging and Radiation Sciences. Available at: <https://linkinghub.elsevier.com/retrieve/pii/S1939865412001853>.
- [5] 'Seventh-generation CT', Physics of Medical Imaging, vol. 9783, 2016. doi.org/10.1117/12.2214319
- [6] J. R. Leyhe, 'Latest generation of flat detector CT as a peri-interventional diagnostic tool: A comparative study with multidetector CT', Journal of NeuroInterventional Surgery, vol. 9, no. 12, pp. 1253-1257, 2017. doi.org/10.1136/neurintsurg-2016-012866
- [7] Murray, N. et al. (2019) 'Dual-energy CT in evaluation of the acute Abdomen', Radiographics, 39(1), pp. 264-286. doi.org/10.1148/rg.2019180087
- [8] C. Méndez García, S. García Ruiz, and C. Franco, 'Anatomy of the abdominal wall', in Advances in Laparoscopy of the Abdominal Wall Hernia, 2014, pp. 7-22. doi.org/10.1007/978-1-4471-4700-8_2
- [9] M. Carstens, 'The Dresden Surgical Anatomy Dataset for Abdominal Organ Segmentation in Surgical Data Science', Scientific Data, vol. 10, no. 1, pp. 1-8, 2023. doi.org/10.1038/s41597-022-01719-2
- [10] Project, S. et al. (no date) Role of triple phase computed tomography 6.

How to Cite: Ekta Singh. (2025). Role of computed tomography scanner for different phase study of abdomen, Journal of Prevention, Diagnosis and Management of Human Diseases (JPDMHD), 5(1), 1-19. <https://doi.org/10.55529/jpdmhd.51.1.19>

BIOGRAPHIE OF AUTHOR



Ekta Singh^{ORCID}, is affiliated with the Department of Paramedical Sciences, Radiology, Netherlands. She specializes in computed tomography (CT) imaging, focusing on abdominal scans, imaging protocols, and patient safety. Her research interests include advanced CT techniques such as triple-phase and dual-source CT, with an emphasis on optimizing diagnostic accuracy and clinical outcomes. Email: ekta75287@gmail.com