


Research Paper



## The effect of using *Astragalus spinosus* extracts as a treatment for *Leishmania* parasite in terms of histological changes

Lara Musaad Juwad<sup>1\*</sup>, Prof. Dr. Omaima Ibrahim Mahmood<sup>2</sup> ,

Assit. Prof. Dr. Bader khatlan Hameed<sup>3</sup> 

<sup>1\*,2,3</sup>Microbiology Branch, College of Veterinary Medicine, University of Tikrit Iraq.

### Article Info

#### Article History:

Received: 12 April 2023

Revised: 15 June 2023

Accepted: 24 June 2023

Published: 09 August 2023

#### Keywords:


Effect

Astragalus Thistle Extracts

Treatment

Leishmania Parasite

Histological Changes



### ABSTRACT

**Background:** In the experimental study on laboratory animals, the alcoholic extract of *Astragalus spinosus* was used on rabbits at a concentration of 75% in the first group. Objective: The aqueous extract of *Astragalus spinosus* was also used on mice at a concentration of 75% in the second group to treat the ulcer caused by *Leishmania* parasite.

**Results:** It was observed that the ulcer diameter started decreasing until it completely disappeared after 22 days from the start of the experiment. The ulcer size decreased from 5 mm after three days of the experiment to 1 mm after twenty days of the experiment, and then it completely disappeared after 22 days from the start of the experiment. The epidermal cells of the skin organized in rows surrounded from the outside by keratin material in the form of dark-colored threads, while the dermis contained numerous bundles of fibrous tissue with infiltrated white blood cells and macrophages around the hair follicles.

**Conclusions:** The role of *Astragalus spinosus* extracts in healing the skin tissues infected with *Leishmania* parasite involves reducing inflammation and stimulating the immune system. This is due to the active compounds present in *Astragalus spinosus*, such as flavonoids and triterpenoids, which possess anti-inflammatory and antioxidant properties. These properties make it effective in treating skin injuries.

#### Corresponding Author:

Lara Musaad Juwad

Microbiology Branch, College of Veterinary Medicine, University of Tikrit Iraq.

Email: [ahmeedgold1000@gmail.com](mailto:ahmeedgold1000@gmail.com)

Copyright © 2023 The Author(s). This is an open access article distributed under the Creative Commons Attribution License, (<http://creativecommons.org/licenses/by/4.0/>) which permits unrestricted use, distribution, and reproduction in any medium, provided the original work is properly cited.

## 1. INTRODUCTION

Leishmaniasis is a parasitic disease caused by Leishmania parasites. It is transmitted to humans and mammals, such as rodents and dogs, through the bite of sandflies. It is prevalent in over 90 countries worldwide, including North and South America, Africa, Asia, and Southern Europe. The disease has a significant global impact, with a high number of widespread cases. Various social, economic, and environmental factors increase the risk of infection. The estimated global prevalence is around 12 million cases, with a continuous increase and 1.5-2 million new cases each year [1]. This parasite causes several clinical forms in mammals, affecting the skin, mucous membranes, and internal organs. It belongs to the Trypanosomatidae family and presents in four main forms: cutaneous leishmaniasis (CL), diffuse cutaneous leishmaniasis, mucocutaneous leishmaniasis, and visceral leishmaniasis or kala-azar [2]. Cutaneous leishmaniasis (CL) is the most common form, caused by Leishmania major parasites that infect humans as the definitive host, residing inside macrophage cells, with the amastigote form. The promastigote stage is found in the sandfly vector (Phlebotomus sp.).

## 2. METHODOLOGY

### 2.1. Hardware and Tools

Table 1 indicates the most important devices and tools that were used in the experiment.

Table 1. Equipment and Materials used in the Research

No.	Device/Tool	Origin
1	Vacuum tube	China
2	Blood collect tube	China
3	Magnetic stirrer	Germany
4	Electric blender	China
5	Autoclave	Britain
6	Glass beaker	China
7	Glass slides	China
8	Hemocytometer chamber	China
9	Incubator	Jordan
10	Cover slides	China
11	Cotton	China
12	Pipette tips	China
13	Gloves	Jordan
14	Light microscope	Germany
15	Sensitive balance	China
16	5 ml Syringe	UAE
17	Benzin burner	China
18	Automatic pipette	China
19	Freezer	Turkey
20	Soxhlet apparatus	China

### 2.2. Chemicals Used

Table 2. Chemicals used in the Research

No.	Chemical/Material	Origin
1	Chloroform	Germany
2	RPMI 1640 medium	Germany
3	Giemsa stain	China
4	Pentostam	Jordan

5	Ethanol alcohol	Turkey
6	Methanol alcohol	Turkey
7	Potassium chloride	Britain
8	Sodium chloride	Britain
9	Sodium bicarbonate	Belgium
10	D-glucose	India
11	Calcium chloride dihydrate	Germany
12	Distilled water	Iraq
13	Fetal calf serum	Germany
14	Gentamicin	Spain
15	Nystatin	China
16	Brain heart infusion agar	India
17	Blood agar	India

### 2.3. Samples Collection

Samples were collected from patients attending Samarra General Hospital and its adjacent areas during the period from September 2021 to May 2022, according to what is recorded in the database for each patient diagnosed by doctors. A total of 250 samples were taken from confirmed cases of cutaneous leishmaniasis. Cutaneous leishmaniasis infections were sorted from non-parasitic causes, and all their information was recorded according to the attached form.

### 2.4. Isolate the Parasite from the Infection Area and Culture it

This is done by injecting 0.1 of the saline solution under the patient's skin using a syringe with a capacity of 1 milliliter, then the liquid is withdrawn from under the skin, provided that the syringe contains a little bit of the patient's blood, and then the contents of the syringe were placed in a culture medium in the laboratory in an uncontaminated environment. The media was prepared to grow the parasite at a temperature of 26-28 °C, then the solution and the contents were left for a period of 24 hours, and finally the components were examined to ensure the presence of the parasite in an anterior flagellate stage [3].

### 2.5. Calculate the Number of Parasites

The number of parasites is calculated in two steps as follows:

1. Milliliter of the culture medium containing the Leishmania parasite was taken and placed in a separate tube, then 9 milliliters of distilled water was added to it, and after stirring and shaking the mixture, it became diluted in a ratio of 10: 1.
2. Using a (pipette) an amount of 10 microliters was taken from the previous tube with which water was mixed, then placed on a special box used for counting blood cells, a hemocytometer, and then a glass cover box was placed to calculate the number of parasites under a microscope at 400X magnification and according to the following equation: Number of parasites In 1 milliliter = number of parasites X 64 squared 25 X X degree of dilution X 105 (Real 2020 ).

### 2.6. Plant Collection and Preparation

The roots of the Astragalus spinosus plant were collected from private farms and matched with sources documenting taxonomic plant species. The roots were washed with water to remove dust, suspended matter and dirt. Then the roots were dried well in the oven at a temperature of 45 °C, then crushed and cut using an electric pulverizer to become a powder, and kept in a sealed container until extracted.

### 2.7. Staining of Tissue Sections

The histological sections of the elected members were prepared according to what came in the source (Luna, 1968), which are summarized as follows:

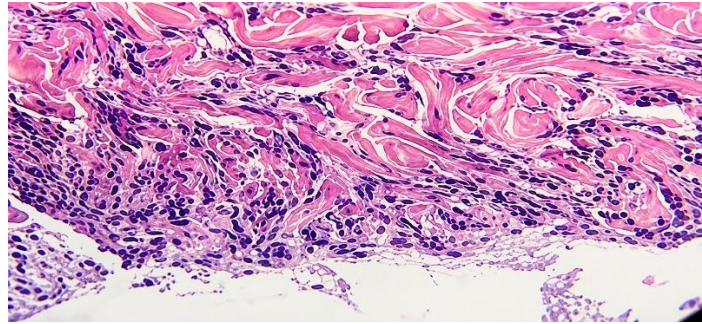
- **Fixation:** The organs (extracted from experimental groups) were fixed with 10% formalin fixative for 48 hours.
- **Washing:** The samples were washed with running tap water for half an hour to remove excess fixative from the tissue.
- **Dehydration:** The samples were passed through an ascending series of ethyl alcohol (70%, 80%, 90%, 100%) for the purpose of drawing water from the samples for two hours for each concentration by manual passes.
- **Clearing:** Xylene was used for clarification, due to its property of making it more transparent, for a period of 25 minutes.
- **Infiltration:** The samples were placed in molten paraffin wax with a melting point of (-5856°) in an oven at a temperature of (60°) for a period of (30) minutes, repeated twice.
- **Embedding:** Samples were buried with the same type of wax by pouring the molten wax quietly into a special iron mold. Information about the member was written on a small piece of paper and placed with forceps and attached to the sides of the iron mold. A hot needle was passed near the model to get rid of bubbles around the sample. found, then left to cool and harden, and then removed from the mold after making sure that it has hardened by using the mold cooling
- **Sectioning:** The mold was placed on the stand installed on the rotary microtome, and the samples were cut with a thickness of (5) micrometers, and then transferred to a warm water bath at a temperature of (45 °) for the purpose of fabric brushing, after which the sections were lifted on a glass slide marked with a pen Massi (organ type and transaction number) before wiping it with albumin. The slide is placed on a heat surface at a temperature of (40°C) and left to dry for 24 hours.
- **Staining:** After completing the process of drying the glass slides, the staining process was carried out as follows:
  1. The glass slides containing the tissue sections were placed in special pots containing xylene solution for the purpose of melting the wax for 5 minutes.
  2. The slides were passed through a series of decreasing concentrations of ethyl alcohol (100% - 70%) for a period of (4) minutes for each concentration. Sections were stained with hematoxylin for (5) minutes and washed in running tap water for the purpose of color discrimination. After that, the sections were colored with eosin solution for (40) seconds and washed in glass dyeing vessels (70%) with alcohol for (5) seconds for the purpose of distinguishing the color.
  3. The slides were passed through an ascending series of alcohol concentrations (70%-100%) for (3) minutes for each concentration, and the slides were placed in glassware containing xylene for (5) minutes for leaching.
- **Mounting:** The sections were covered with a cover slide after placing a small drop of (D.P.X), then the slides were left on a hot plate at a temperature of (40°) for the purpose of accelerating drying, and then kept in their boxes.

### 3. RESULTS AND DISCUSSION

#### 3.1. Histological Study

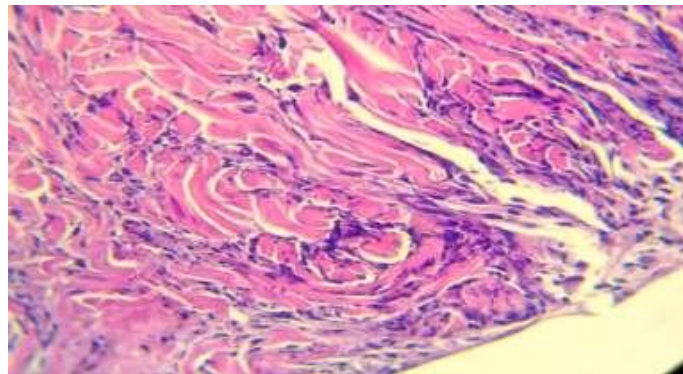
##### 3.1.1. Control Group (Experimentally Infective)

Figure 1 showed the presence of wide infiltration of white blood cells in the dermis of the skin with epidermis, as they were present in the loose connective tissue between bundles of colloids that were found in different directions.



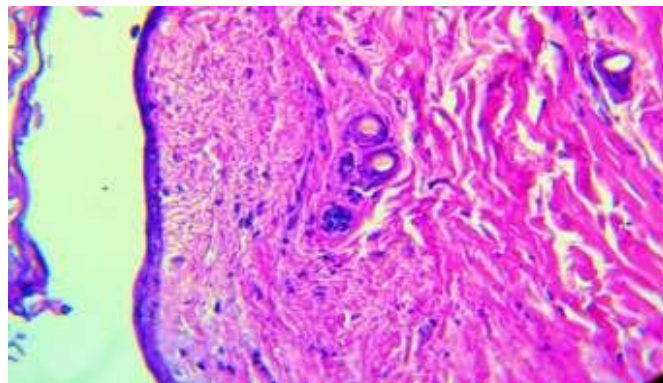
**Figure 1.** Skin Texture, Disappearance of the Epidermis (A), Infiltration of Leukocytes into the Dermis (B), Bundles of Colloidal Fibers in the Dermis (C), in Different Directions H&E X40

**Figure 2** shows that there is a large and wide infiltration of inflammatory white blood cells in the dermis area of the skin with macrophages, as they spread to the periphery of the dermis through colloidal fibers, with the appearance of the epidermal site in a non-distinctive vestigial form, and white blood cells were found in that area as in Photo below.



**Figure 2.** Epidermis Appearing Vestigial (A) Infiltration of White Blood Cells and Macrophages (B) in the Dermis, Bundles of Colloidal Fibers in Different Directions H&E X40

**Figure 3** shows that the skin epidermis is very thin and consisted of small degenerated epithelial cells that contained cytoplasm in which two types of cells were crumbled and missing, Karyolysis and karyohexis with separation of the keratin layer from the surface of the epidermis. The dermis area contained extensive degeneration of part of the skin Colloidal fibers with atrophy and loss of many of those bundles in some areas of the dermis to the layers to the depth of the dermis in which there are limited number of hair follicles surrounded by a focal aggregation of white blood cells as in the picture below.



**Figure 3.** Epidermis of the Skin with Degeneration Squamous Cells (A) Keratin from the Epidermis of the Skin (B) Degeneration, Dissociation and Atrophy of Colloids in the Dermis (C) Hair Follicles (D) Colloidal Fiber Bundles (E) in the Hypodermis H&E X40

Figure 4 showed that there was severe degeneration of the epidermal cells with the loss of the features of the squamous cells in which they appeared in the form of a dark blue and narrow line, in addition to the sloughing of the keratin layer from the surface of the epidermis. On the surface of the epidermis at the area of degeneration of the dark-colored epidermal cells, and between the hair follicles, a number of white blood cells were found diffusely with flagellate cells.

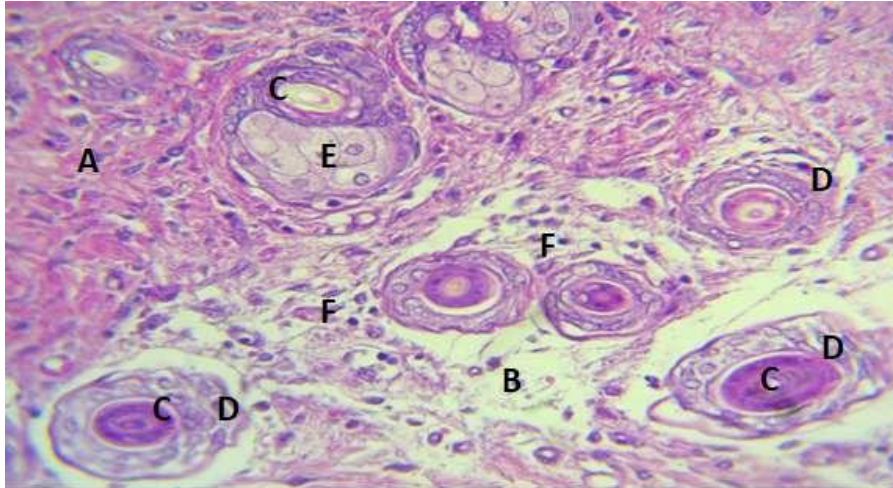


Figure 4. Degeneration of Epidermal Cells and their Appearance as a Dark Blue Line (A) Hair Follicles (B) in the Dermis Surrounded by White Blood Cells (C) Imaginary Glands (D) Dissociation of Colloidal Fiber Bundles (E) in the Subdermis

### 3.2. The Treated Group

Figure 5 showed that the layer under the dermis and the dermis contained hair follicles consisting of the pulp and follicular cells of the hair in the cortex, reaching the sebaceous glands and the fibrous tissue around the follicles, in which a number of white blood cells infiltrated with macrophages.

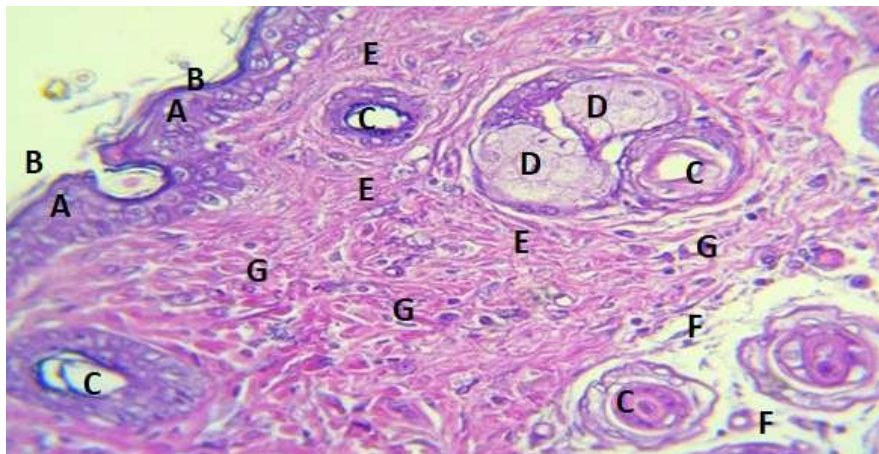
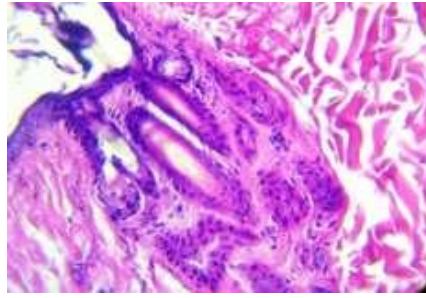


Figure 5. Layer Dermis (A) Subdermis (B) Hair Follicles and Medulla (C) Cortex Dandruff (D) Sebaceous Glands (E) White Blood Cells (F) CHEX40

Figure 6 shows the epidermis of the skin in which there are squamous epithelial cells consisting of several rows. Some cells in the epidermis have vacuolar degeneration, and the outer row in the epidermis is covered with keratin threads. Blood cells. Some macrophages exist between bundles of colloidal fibers in the dermis and under the dermis. Hair follicles around glands extend the sebum is in the form of a pale fibrous layer surrounded by fibrous tissue.



**Figure 6.** Normal Skin Epidermis (A) Keratin Strands (B) Keratin Strands Hair Follicles (C) Colloidal Fiber Bundles in the Dermis (E) and Subdermis (F) White Blood Cells (G) H&E X40

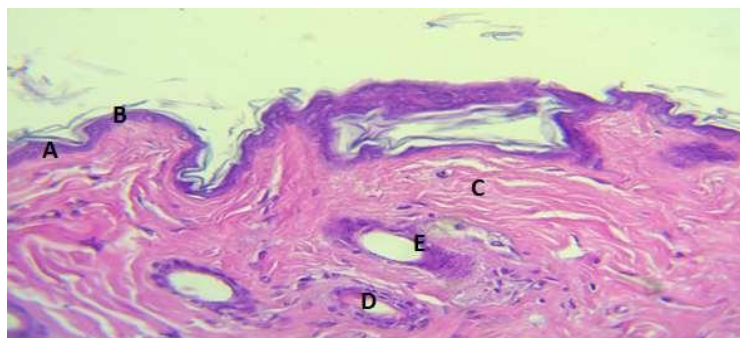
These results were consistent with the findings of [4], who showed in their analysis of 50 cases with confirmed CL infection the presence of varying degrees of inflammatory infiltrates, characterized by an abundance of plasma cells followed by lymphocytes. The skin exhibited both destruction and atrophy accompanied by hyperkeratosis, cellular exudate, and morphological changes.

They also aligned with [5], who observed skin alterations such as cell exudation in CL, highlighting the importance of the skin in immune regulation of the disease. Additionally, the lesions demonstrated the presence of ulcers, focal necrosis, and granulomatous tumors. The well-organized granulomatous tumors with multinucleated giant cells were associated with the immune system's attempt to eliminate the parasites. It was also noted that the parasite load gradually decreased with the development of granulomatous inflammation. The well-defined granulomatous tumor formation showed a positive correlation with a low parasite load.

These results differed from those reported by [6], whose study analyzed skin biopsies and found prominent expression of helper T cell 1 cytokines, with increased levels of IFN- $\gamma$  in healing lesions. Similarly, (Herath et al. 2010) did not observe prominent necrosis in their study results; instead, it was focal and present in a minority of cases. However, plasma cells were the predominant cell type in most cases, and activated helper T cells (IFN- $\gamma$  and TNF- $\alpha$ ) were found to activate infected macrophages to destroy the parasites.

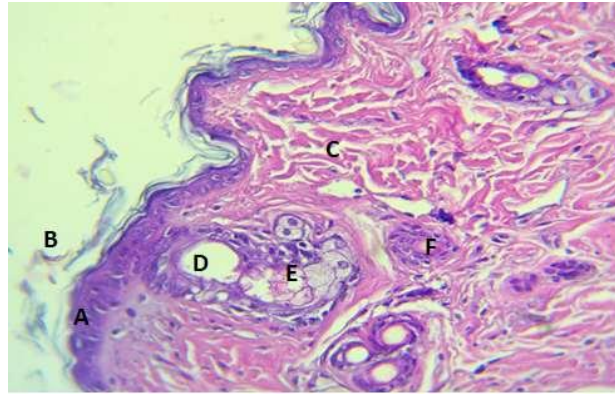
### 3.3. The Control

The epidermis of the skin contained degenerated epithelial cells with unclear features and surrounded from the outside by strands of loose keratin, and the dermis was composed of bundles of colloidal fibers with the presence of fibroblasts in them, in addition to the sweat ducts lining two rows of cells (Figure 7).



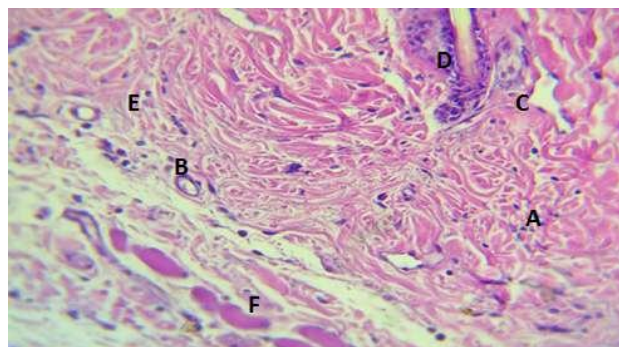
**Figure 7.** Epidermis of the Skin with Degenerative Epithelial Cells (A) Keratin Compaction (B) Dermis with Bundles of Colloidal Fibers (C) Transverse Duct (D) with Broken Cells (E) H&E X40))

The epidermis of the skin contained two rows of squamous epithelial cells that showed degeneration and their nuclei thickened and the nuclei of other cells were broken surrounded from the outside by keratin threads. The hair sheath also found some ducts of sweat secretion (Figure 8).



**Figure 8.** Skin Epidermis with Pigmented Degenerated Squamous Epithelial Cells (A) Keratin Fibers (B) Loose Epithelial Fiber Bundles (C) in the Dermis, Hair Follicles (D) Sebaceous Glands (E) Sweat Gland (F) H&E X40

The dermis of the skin contained separate bundles of colloidal fibers and surrounded by a number of inflammatory white blood cells and macrophages. The hair shaft was also found surrounded by follicular epithelial cells formed at the root of the hair. The dermis of the skin contained capillary blood vessels devoid of pulp that extended to the deep areas of the dermis (Figure 9).



**Figure 9.** Dermis of the Skin with Disjuncted Colloidal Fiber Bundles (A) Inflammatory Leukocytes (B) Hair Root (C) Hair Shaft (D) Bloodless Capillary Blood Vessels (E) H&E X40 Skeletal Muscles (F)

#### 4. CONCLUSION

In conclusion, the study explored the effect of Astragalus thistle extracts as a treatment for Leishmania parasites, focusing on histological changes. The results indicated that the parasite's effectiveness was excellent when using the liquid medium RPMI 1640, but its efficacy decreased after a short period. On the other hand, the NNN culture medium provided a good environment for parasite growth and reproduction, although it was prone to contamination.

The study also revealed some significant findings regarding the infection rate of Leishmania. In January, there was a higher incidence of infection, with males being more affected than females. Additionally, children under the age of five had the highest infection rate.

Furthermore, the study highlighted the difference in infection rates between dry and wet types of cutaneous leishmaniasis, with the dry type showing a higher incidence. Moreover, the alcoholic extract of Astragalus thistle demonstrated effectiveness in inhibiting the promastigote stage in laboratory settings. The water and alcoholic extracts of Astragalus thistle also proved their efficacy in inhibiting the amastigote stage when combined with medical vaseline on laboratory animals infected with cutaneous leishmaniasis. Histological sections of cutaneous leishmaniasis infection revealed the presence of inflammatory cells, tissue fibrosis, and an accumulation of lymphocytes, macrophages, and plasma cells in the affected area. These sections also confirmed the presence of the parasite in the infected tissues.

### Acknowledgments

Praise be to Allah, the Lord of all worlds. May peace and blessings be upon the noblest of prophets and messengers, our master Muhammad, his family, his companions, and those who follow them in righteousness until the Day of Judgment.

I thank Allah Almighty for His grace, as He has enabled me to accomplish this work through His blessings. To Him belongs all praise, first and last.

I would like to express my gratitude to those noble individuals who extended their helping hand during this period, particularly my research supervisor, Dr. Amima Ibrahim Mahmoud. She exerted effort in assisting me, encouraging and motivating me to conduct this research. She deserves the reward from Allah, and I offer her my utmost appreciation. May Allah protect her, grant her good health and well-being, and bless others with her knowledge.

I would also like to thank Assistant Professor Badr Khatlan Hamid for his assistance and continuous support throughout the research and the writing of this thesis.

Lastly, I extend my sincere thanks and appreciation to the professors of the College of Veterinary Medicine.

### Funding Information

This research received no specific grant from any funding agency in the public, commercial, or not-for-profit sectors.

### Author Contributions Statement

Name of Author	C	M	So	Va	Fo	I	R	D	O	E	Vi	Su	P	Fu
Lara Musaad Juwad	✓	✓	✓	✓		✓		✓	✓	✓	✓		✓	
Prof. Dr. Omaima Ibrahim Mahmood	✓		✓	✓	✓		✓	✓	✓	✓	✓	✓		✓
Assit. Prof. Dr. Bader khatlan Hameed	✓		✓	✓	✓		✓	✓		✓	✓		✓	✓

C : Conceptualization

M : Methodology

So : Software

Va : Validation

Fo : Formal analysis

I : Investigation

R : Resources

D : Data Curation

O : Writing - Original Draft

E : Writing - Review & Editing

Vi : Visualization

Su : Supervision

P : Project administration

Fu : Funding acquisition

### Conflict of Interest Statement

The authors declare that there are no conflicts of interest regarding the publication of this paper.

### Informed Consent

All participants were informed about the purpose of the study, and their voluntary consent was obtained prior to data collection.

### Ethical Approval

Not Applicable.

### Data Availability






The data that support the findings of this study are available from the corresponding author upon reasonable request.

## REFERENCES

- [1] K. E. Benallal, R. Garni, Z. Harrat, P. Volf, and V. Dvorak, 'Phlebotomine sand flies (Diptera: Psychodidae) of the Maghreb region: A systematic review of distribution, morphology, and role in the transmission of the pathogens', *PLoS Negl. Trop.*, 2022. [doi.org/10.1371/journal.pntd.0009952](https://doi.org/10.1371/journal.pntd.0009952)
- [2] A. Caroline et al., 'Immune Responses in Leishmaniasis: An Overview, Trop', *Trop. Med. Infect. Dis.*, vol. 2022, 2022.
- [3] N. Hai, R. P. Akhter, and I. Ali, 'Isolation, maintenance and detection of Leishmania parasite by microscopy and culture technique', in 14th International Bhurban Conference on Applied Sciences and Technology (IBCAST), 2017. [doi.org/10.1109/IBCAST.2017.7868052](https://doi.org/10.1109/IBCAST.2017.7868052)
- [4] W. Harshima, G. Nayana, S. Saveen, P. Nishantha, M. Nuwani, and D. Chandu De, 'Histopathology of Cutaneous Leishmaniasis Caused by Leishmania donovani in Sri Lanka', vol. 2020, May 2020. [doi.org/10.1155/2020/4926819](https://doi.org/10.1155/2020/4926819)
- [5] K. González, R. Diaz, and A. F. Ferreira, 'Histopathological characteristics of cutaneous lesions caused by Leishmania Viannia panamensis in Panama', *Revista do Instituto de Medicina Tropical de São Paulo*, vol. 60, 2018. [doi.org/10.1590/s1678-9946201860008](https://doi.org/10.1590/s1678-9946201860008)
- [6] N. H. Manamperi, S. Oghumu, and N. Pathirana, 'In situ immunopathological changes in cutaneous leishmaniasis due to Leishmania donovani', *Parasite Immunology*, 2017. [doi.org/10.1111/pim.12413](https://doi.org/10.1111/pim.12413)

**How to Cite:** Lara Musaad Juwad, Prof. Dr. Omaima Ibrahim Mahmood, Assit. Prof. Dr. Bader khatlan Hameed. (2023). The effect of using Astragalus spinosus extracts as a treatment for Leishmania parasite in terms of histological changes. *Journal Healthcare Treatment Development (JHTD)*, 3(2), 32–41. <https://doi.org/10.55529/jhtd.34.32.42>

## BIOGRAPHIES OF AUTHORS

	<p><b>Lara Musaad Juwad</b>, is a researcher affiliated with the Microbiology Branch, College of Veterinary Medicine, University of Tikrit, Iraq. She is involved in scientific research on parasitic diseases, notably contributing to studies on the treatment of Leishmania parasites using plant extracts, as evidenced by her 2023 publication in the <i>Journal Healthcare Treatment Development</i>. Email: <a href="mailto:ahmeedgold1000@gmail.com">ahmeedgold1000@gmail.com</a></p>
	<p><b>Prof. Dr. Omaima Ibrahim Mahmood</b> , is a Professor in the College of Veterinary Medicine at the University of Tikrit, Iraq. She has authored at least 15 publications with a research focus on parasitology and microbiology, including studies on Leishmania, Cryptosporidium, and Blastocystis hominis in Iraq. She is a long-standing faculty member and a key figure in veterinary microbiology research at Tikrit.</p>
	<p><b>Assit. Prof. Dr. Bader khatlan Hameed</b> , is an Assistant Professor in the Microbiology Branch, College of Veterinary Medicine, University of Tikrit, Iraq. He collaborates on research related to parasitic and microbial diseases, contributing to studies on novel plant-based treatments for parasitic infections such as leishmaniasis.</p>